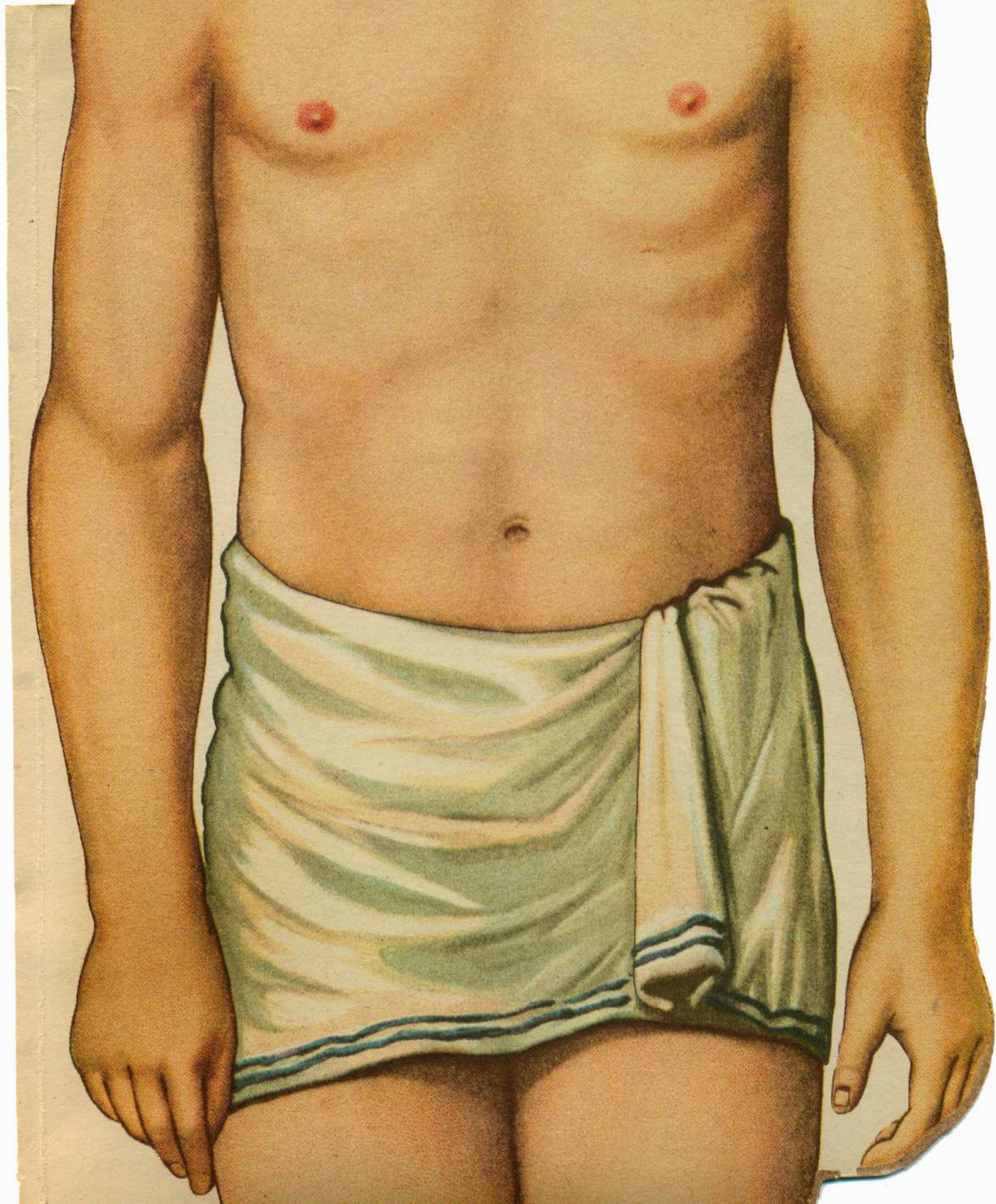
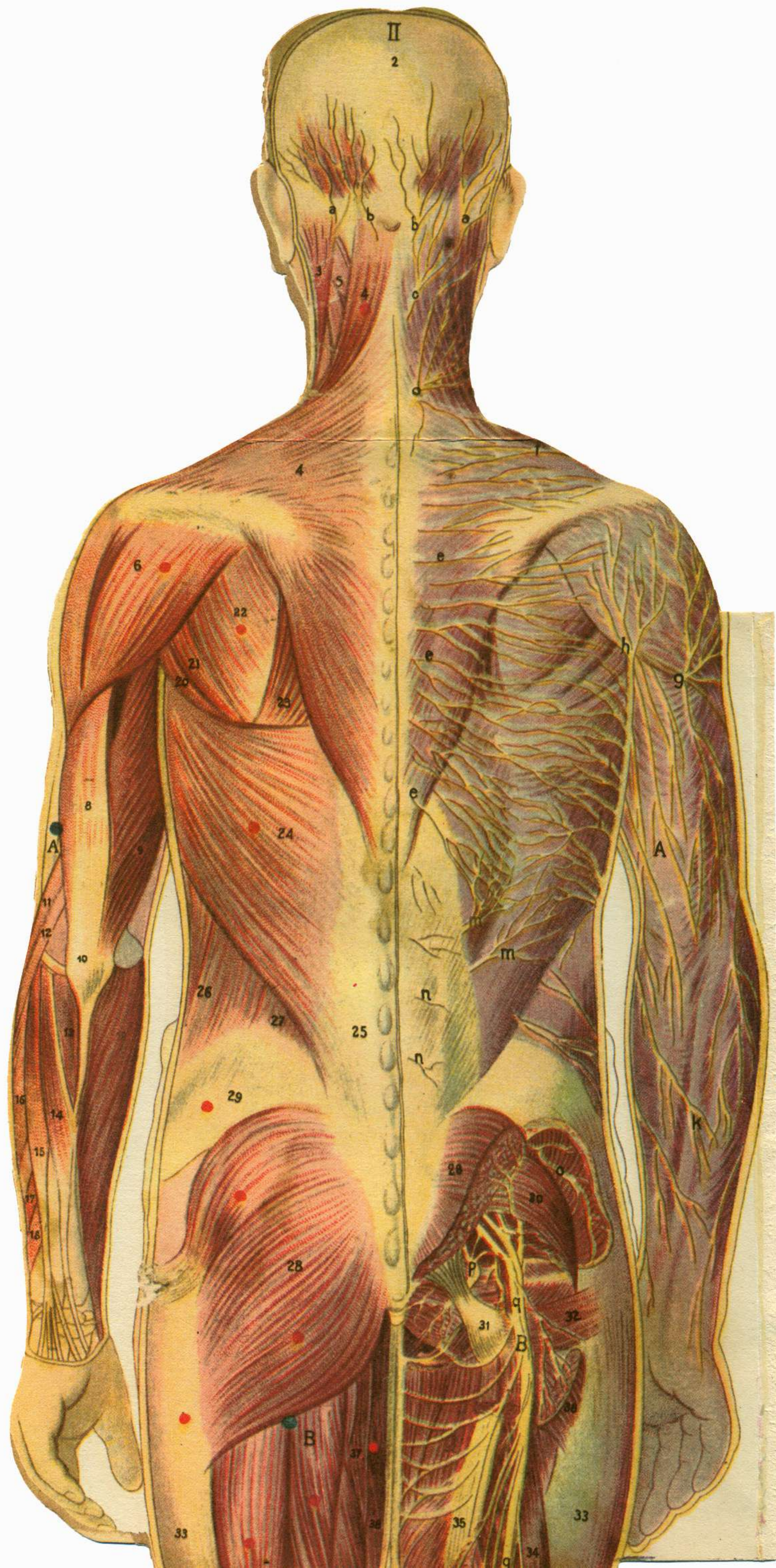
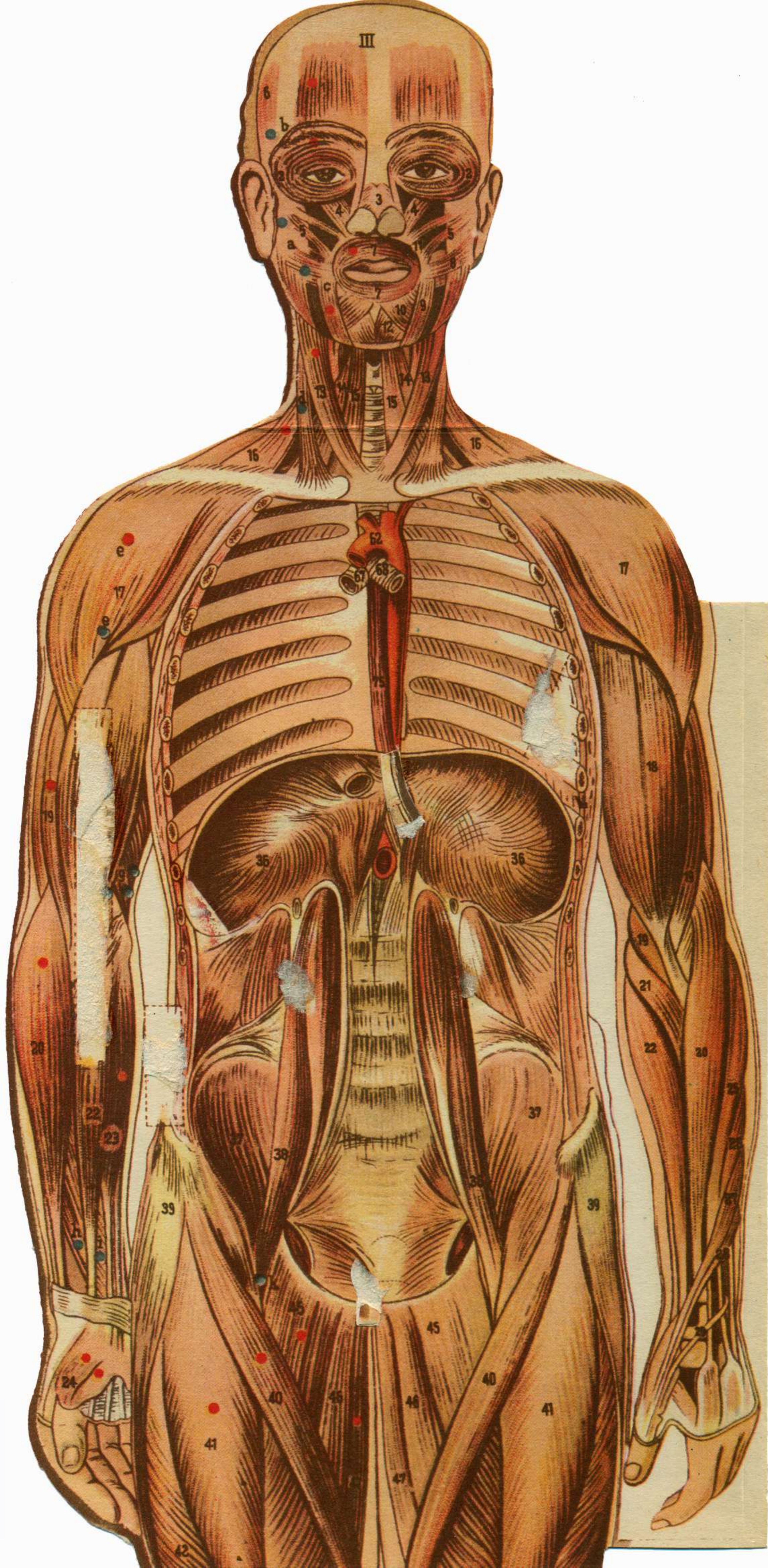
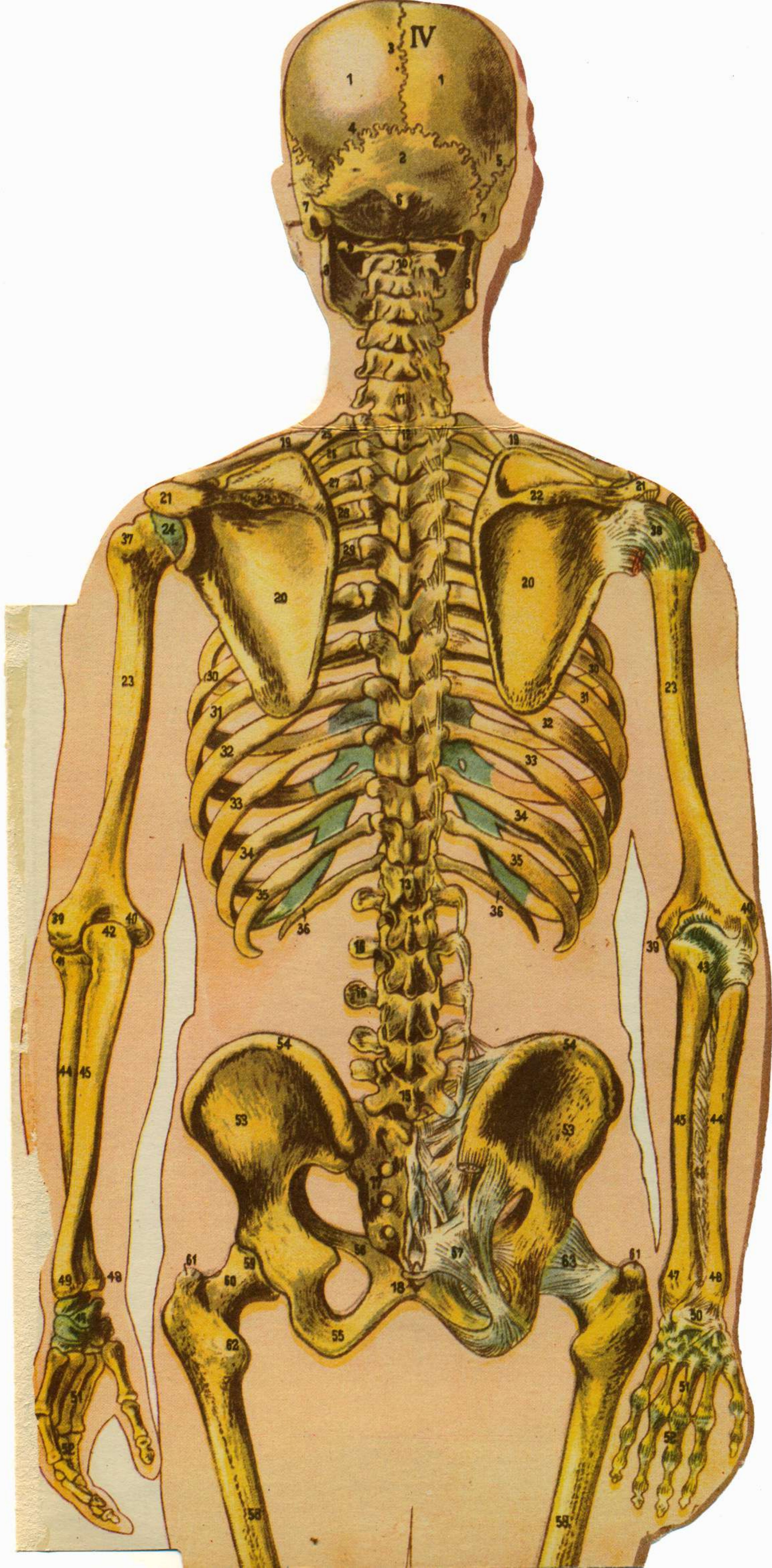


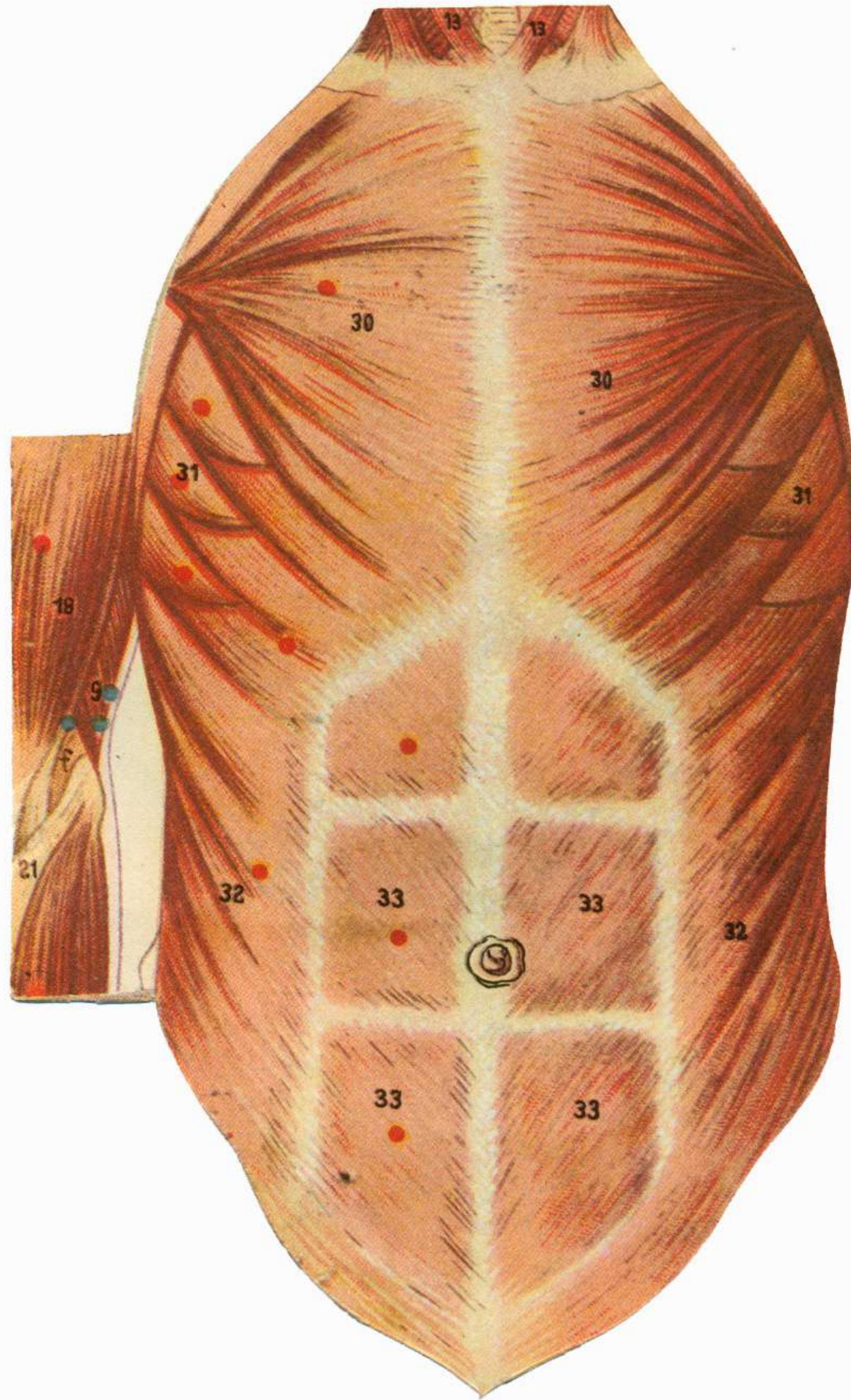
CREASE HERE

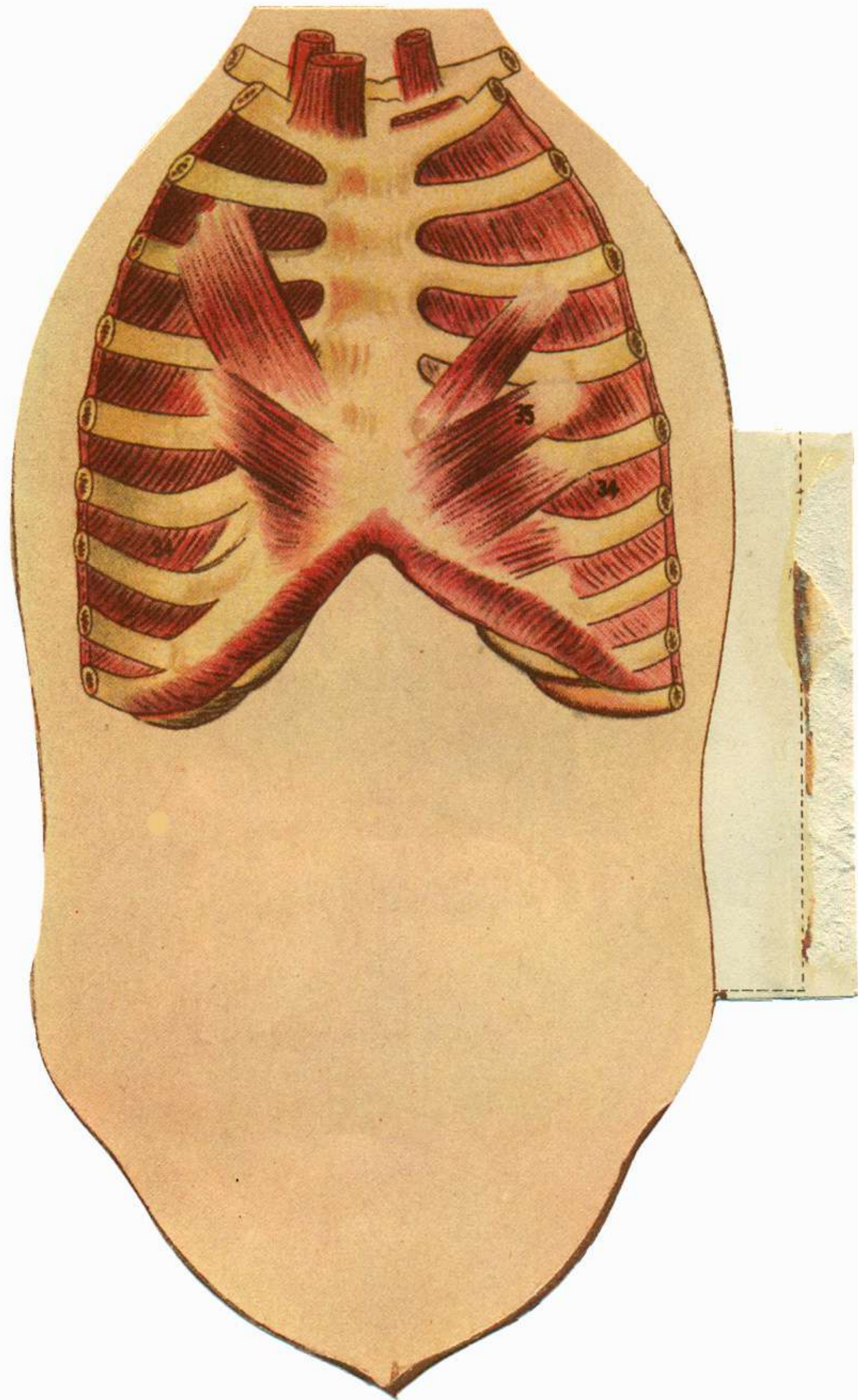


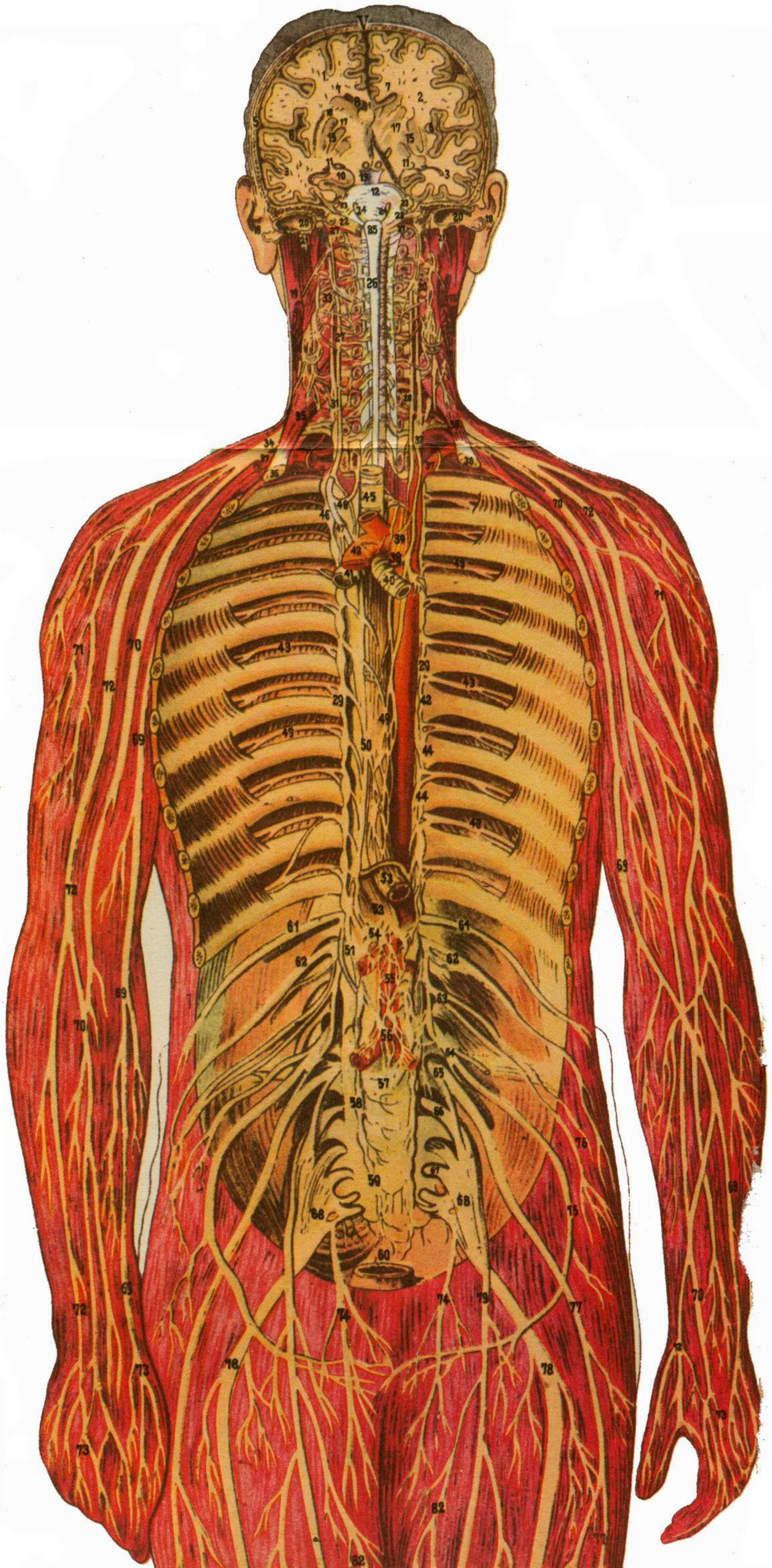



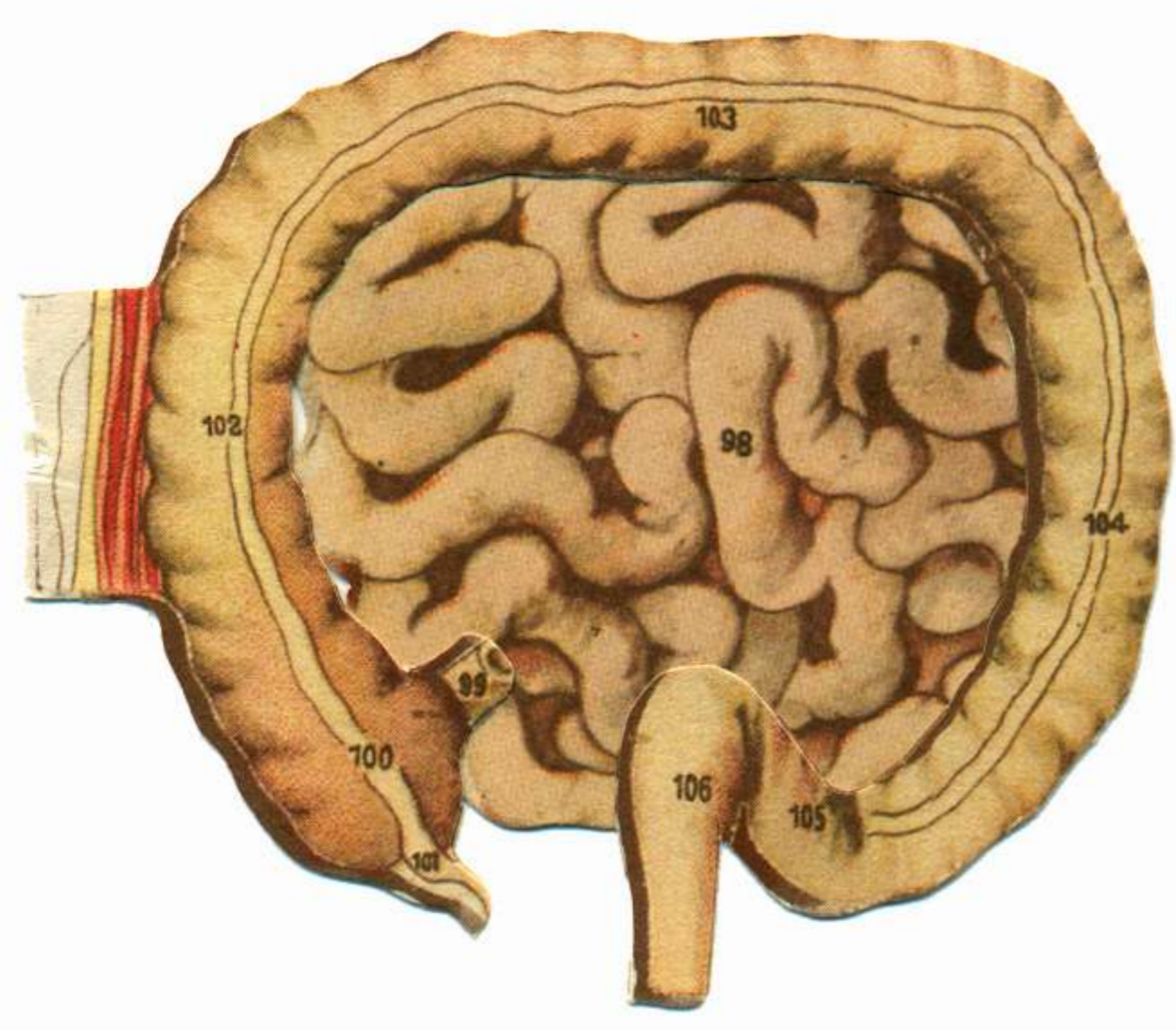
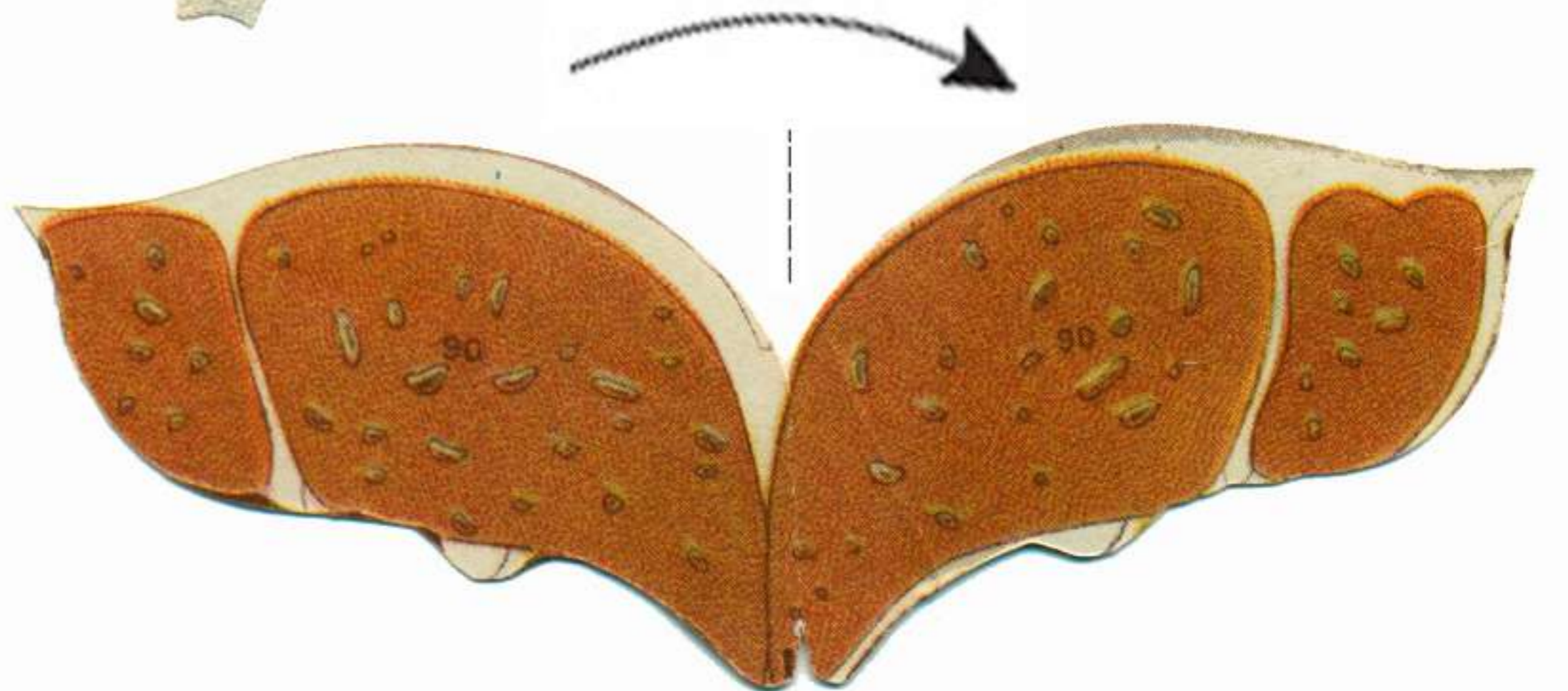
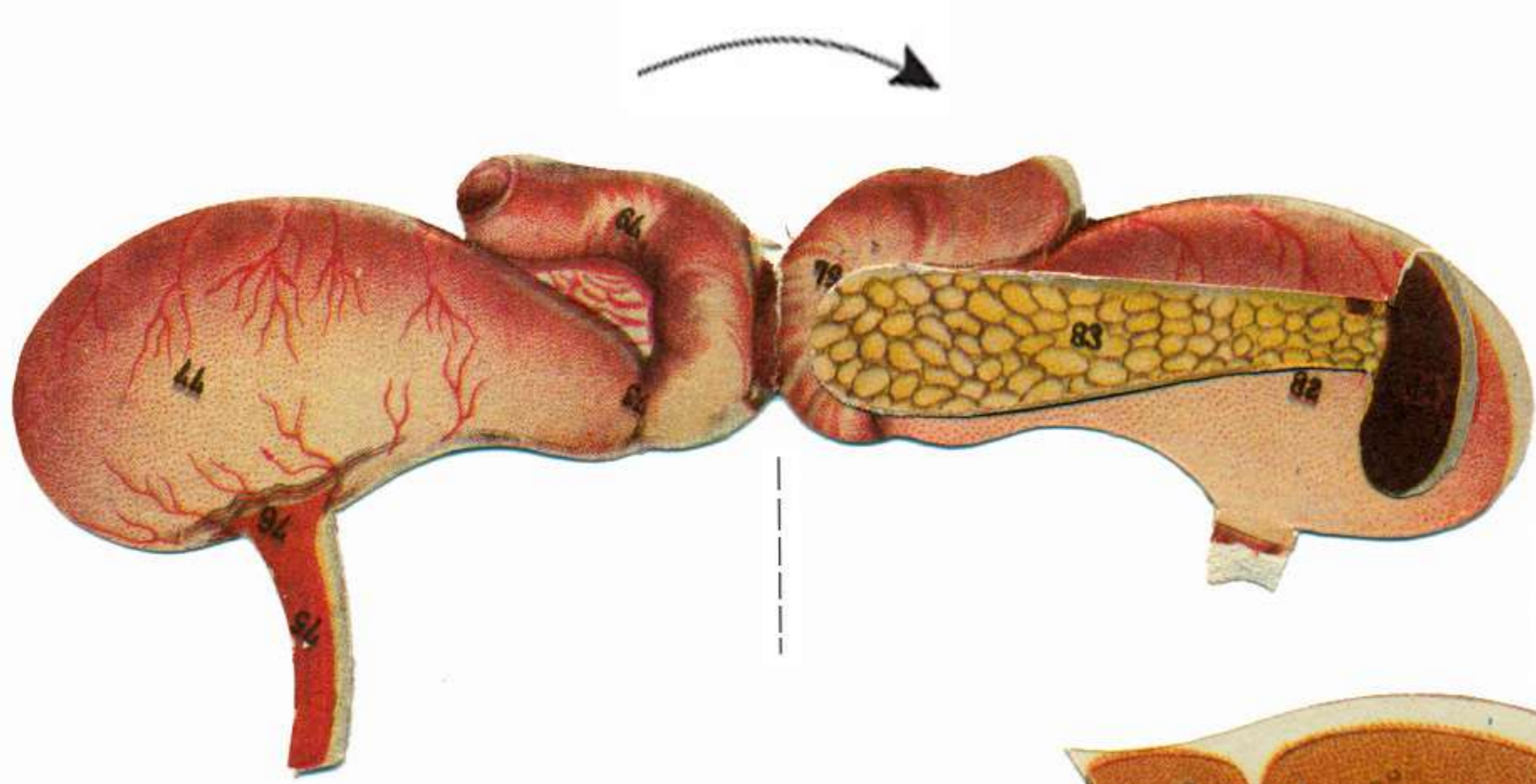


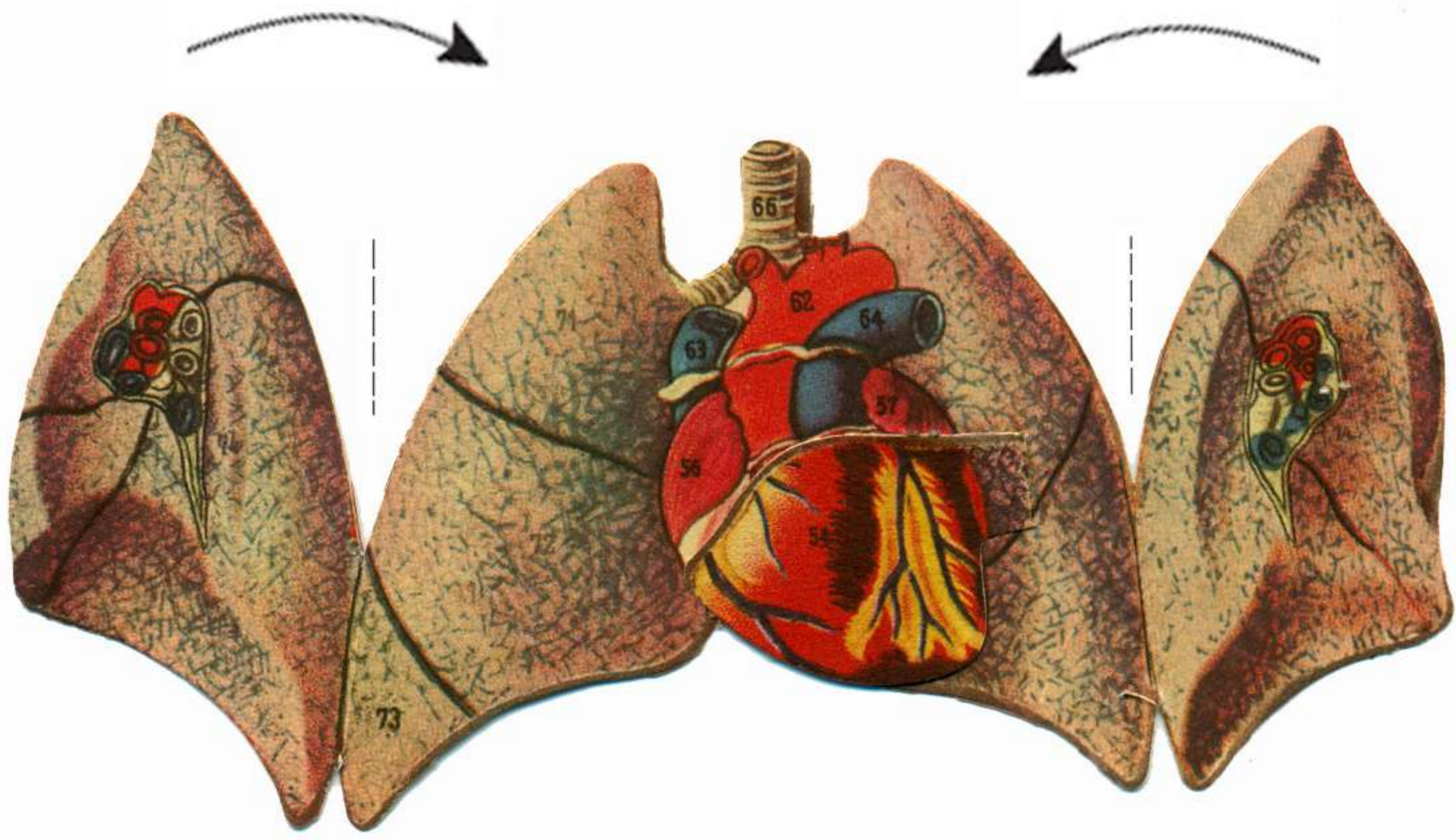


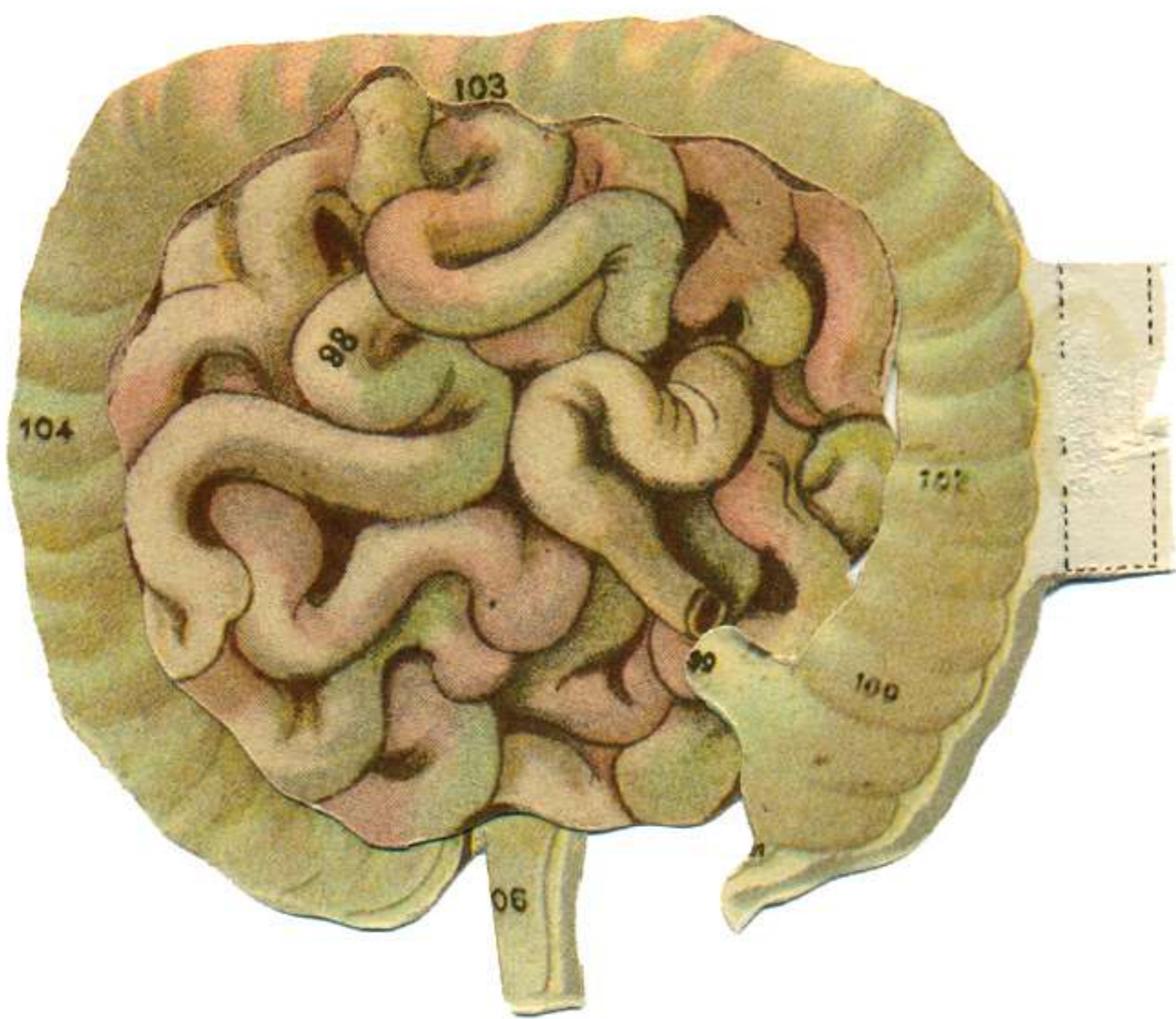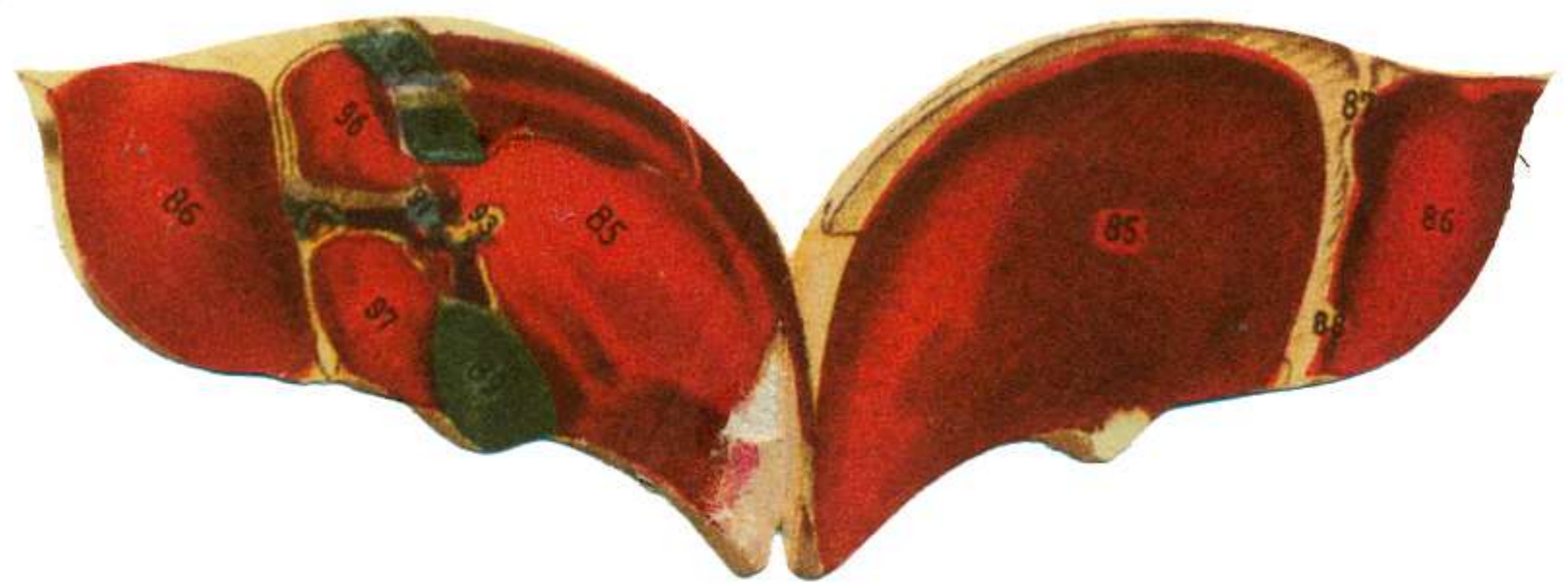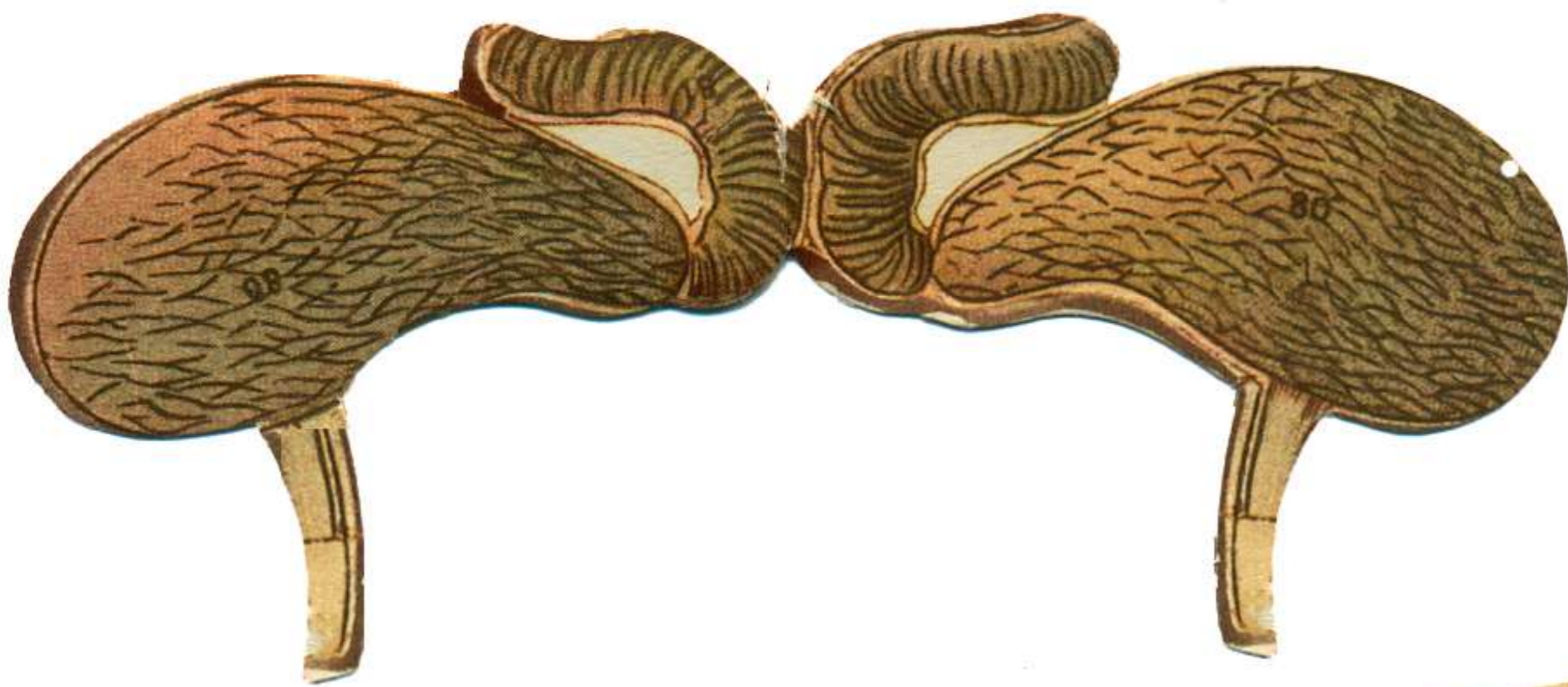
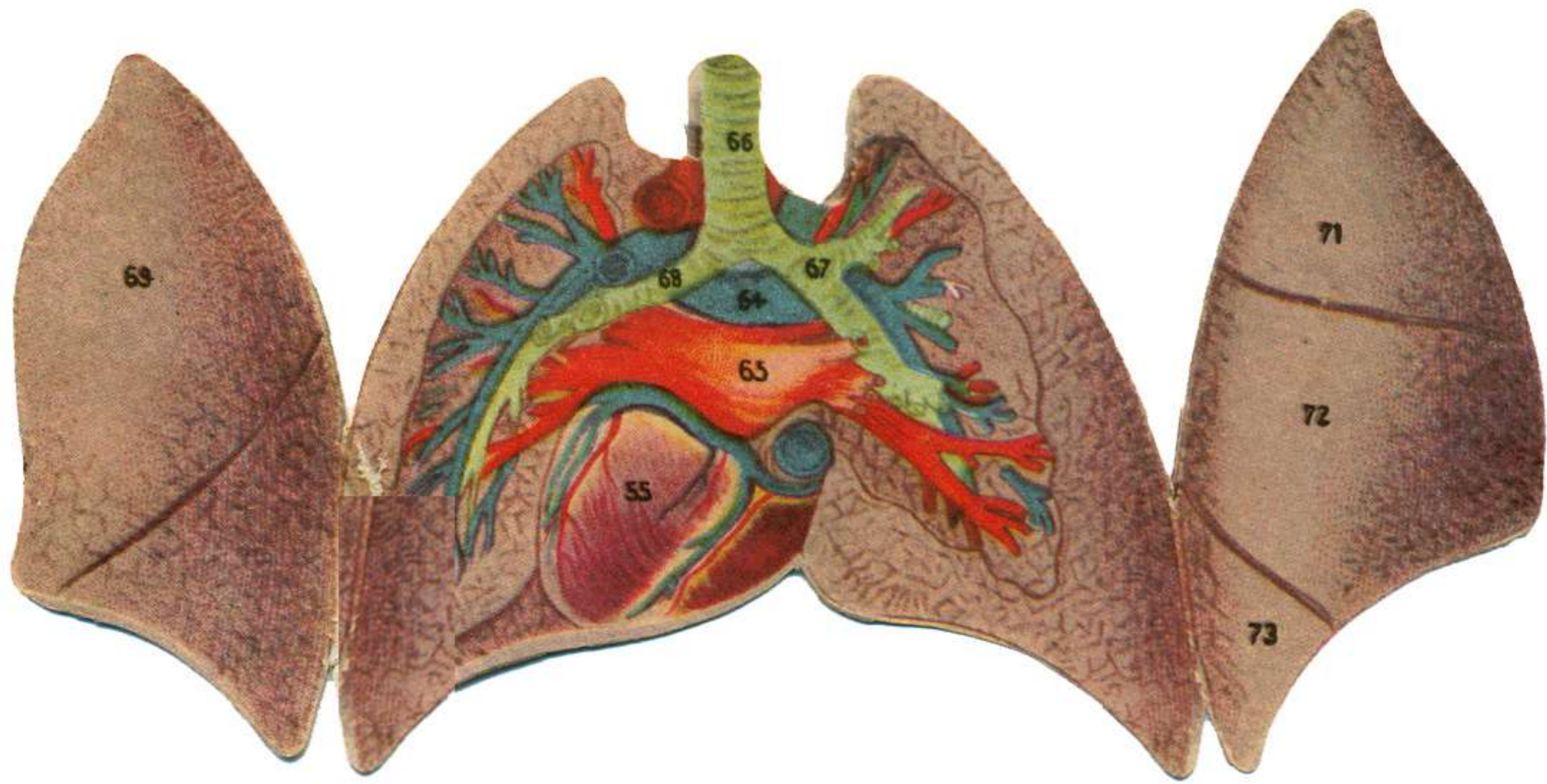












STRUCTURE OF THE HUMAN BODY

MALE : ANATOMICAL SECTIONAL MODEL

- I. EXTERNAL ASPECT**
- II. MUSCLES AND NERVES FROM THE BACK**
1. Occipitalis muscle
 2. Epicranial aponeurosis
 3. Sternomastoid
 4. Trapezius
 5. Splenius
 6. Deltoid
 7. Long
 8. Outer } head of triceps
 9. Inner } head of triceps
 10. Olecranon process of the ulna
 11. Brachioradialis
 12. Extensor carpi radialis longior
 13. Extensor carpi radialis brevior
 14. Extensor carpi ulnaris
 15. Extensor communis digitorum
 16. Extensor carpi radialis brevior
 17. Extensor ossis metacarpi pollicis
 19. Flexor carpi ulnaris
 20. Teres major
 21. Teres minor
 22. Infraspinatus
 23. Rhomboid
 24. Latissimus dorsi
 25. Lumbar fascia (with large group of erector spinae)
 26. External oblique
 27. Internal oblique
 28. Gluteus maximus
 29. Gluteus medius
 30. Piriformis
 31. Ischial tuberosity
 32. Quadratus femoris
 33. External head of quadriceps (still covered with fascia)
 34. Biceps
 35. Semi-membranosus
 37. Adductor magnus
 38. Gracilis
- The blue dots indicate the points of stimulation of the nerves
- The red dots indicate the motor points of the muscles
- A. Point of stimulation of radial nerve**
- B. Point of stimulation of sciatic nerve**
- Nerves on the right side of the body :
- a. Great occipital nerve
 - b. Small occipital nerve
 - c. d. Posterior branches of cervical nerves
- III. MUSCLES FROM THE FRONT, VISCERA, ETC.**
1. Frontalis
 2. Orbicularis palpebrarum
 3. Nasal muscle
 4. Quadratus muscles, composed of three parts (levator labii superioris; alequae nasi; zygomaticus minor)
 5. Zygomaticus major
 6. Temporal muscle
 7. Orbicularis oris
 8. Risorius
 9. Depressor anguli oris
 10. Depressor labii inferioris
 11. Levator anguli oris
 12. Levator menti
 13. Sterno-cleido-mastoid
 14. Omohyoid
 15. Sterno-hyoid
 17. Trapezius
 18. Deltoid
 19. Brachialis anticus
 20. Brachioradialis
 21. Pronator teres
 22. Flexor carpi radialis
 23. Palmaris longus
 24. Muscles of thenar eminence
 25. Extensor carpi radialis longior
 26. Extensor carpi radialis brevior
 27. Extensor ossis metacarpi pollicis
 28. Extensor brevis pollicis
 29. Tendon of extensor longus pollicis
 30. Pectoralis major
 31. Serratus manus
 32. External oblique
 33. Rectus abdominis with tendinous intersections
 34. Intercostal muscles
 35. Triangularis sterni
 36. Diaphragm
 37. Iliacus
 38. Psoas
 39. Tensor fasciae latae
 40. Sartorius
 41. Rectus femoris
 42. Vastus externus
 43. Vastus internus
 45. Pectineus
 46. Adductor longus
 47. Gracilis
- Motor points of muscles in red
- Stimulation points of nerves
- a, b, c. Stimulation points of facial nerve
 - a. Stimulation points of the origin of this nerve
 - b. Stimulation points of the upper branch
 - c. Stimulation points of the lower branch
 - d. Stimulation points of the phrenic nerve
 - e. Stimulation points of the musculo-cutaneous nerve
 - f. Stimulation points of the median nerve
 - g. Stimulation points of the ulnar nerve
 - h. Stimulation points of the median nerve on the forearm
 - i. Stimulation points of the ulnar nerve on the forearm
 - k. Stimulation points of the femoral nerve
- IV. INTERNAL ORGANS OR VISCERA**
54. Right side of heart
 55. Left side of heart
 56. Right auricle with appendage
 57. Left auricle with appendage
 58. Papillary muscles with chordae tendinae
 59. Bicuspid valve
 60. One of the three semi-lunar valves
 61. Interventricular septum
 62. Aorta
 63. Superior vena cava
 64. Pulmonary artery
 65. Pulmonary veins (carrying arterial blood to left side of heart)
 66. Trachea
 67. Right bronchus with divisions in lung
 68. Left bronchus with divisions in lung
- V. SKELETON FROM THE BACK**
1. Parietal bone
 2. Occipital bone
 3. Sacral suture
 4. Lambdoid suture
 5. Squamous suture
 6. Occipital protuberance
 7. Temporal bone
 8. Mandible
 9. Atlas or first cervical vertebra
 10. Axis or second cervical vertebra
 11. Seventh cervical vertebra, with prominent dorsal spine
 12. First thoracic vertebra
 13. Twelfth thoracic vertebra
 14. First lumbar vertebra
 15. Fifth lumbar vertebra
 16. Transverse processes of vertebrae
 17. Sacrum
 18. Coccyx
- V. NERVOUS SYSTEM**
1. Frontal lobe
 2. Parietal lobe
 3. Temporal lobe
 4. Intercerebral fissure separating hemispheres
 5. Lateral fissure of brain
 6. Island of Reil and its convolutions
 7. Corpus callosum
 8. Lateral ventricle
 9. Third ventricle
 10. Hippocampus (in inferior horn of lateral ventricle)
 11. Optic tract
 12. Pons varolii
 13. Crus cerebri (the dark line represents a section through its base)
 14. Caudate nucleus
 15. Lenticular nucleus (consisting of three parts)
 16. Clausstrum
 17. Internal capsule
 18. External ear
 19. Sterno-cleido-mastoid
 20. External auditory meatus
 21. Styloid process
 22. Facial and auditory nerves
 23. Trigeminal nerve
 24. Abducent nerve
 25. Medulla oblongata
 26. Glossopharyngeal nerve
 27. Vagus
 28. Sympathetic nerve
 29. Superior cervical ganglion of sympathetic nerves
 30. Fifth rib
 31. Middle cervical ganglion of sympathetic nerves
 32. Inferior cervical ganglion of sympathetic nerves
 33. Cervical plexus (from anterior branches of first four cervical nerves)
 34. Brachial plexus
 35. Scalenus anticus muscle
 36. First rib (cut across)
 37. Subclavian artery
 38. Left recurrent laryngeal nerve
 39. Cardiac plexus, derived from vagus and sympathetic nerves, supplies ascending aorta, arch of aorta, and pulmonary artery
 40. Left bronchus
 41. Right bronchus
 42. Aorta
 43. Intercostal nerve
 44. Communicating branches between sympathetic and intercostal nerves
 45. Trachea
 46. Second thoracic ganglion of sympathetic
 47. Right vagus
 48. Right recurrent laryngeal nerve
 49. Oesophageal plexus from vagus
 50. Small splanchnic nerve
 51. Great splanchnic nerve
 52. Lesser trochanter
 53. Diaphragm
 54. Lower end of oesophagus at entrance into stomach
 55. Solar plexus of sympathetic
 56. Aortic plexus of sympathetic
 57. Inferior mesenteric plexus
 58. Lumbar ganglion
 59. Sacral ganglion
 60. Rectum
 61. Twelfth intercostal nerve
 62. First lumbar nerve giving origin to ilio-hypogastric nerve
 63. Second lumbar nerve
 64. Third lumbar nerve
 65. Fourth lumbar nerve
 66. Fifth lumbar nerve
 67. Sacral nerves
 68. Sacral plexus
 69. Ulnar nerve
 70. Median nerve
 71. Musculo-cutaneous branches
 72. Radial nerve
 73. Nerves of hand
 74. Obturator nerve
 75. Ilio-inguinal nerve
 76. Ilio-hypogastric nerve
 77. External cutaneous nerve
 78. Sciatic nerve
 79. Crural nerve